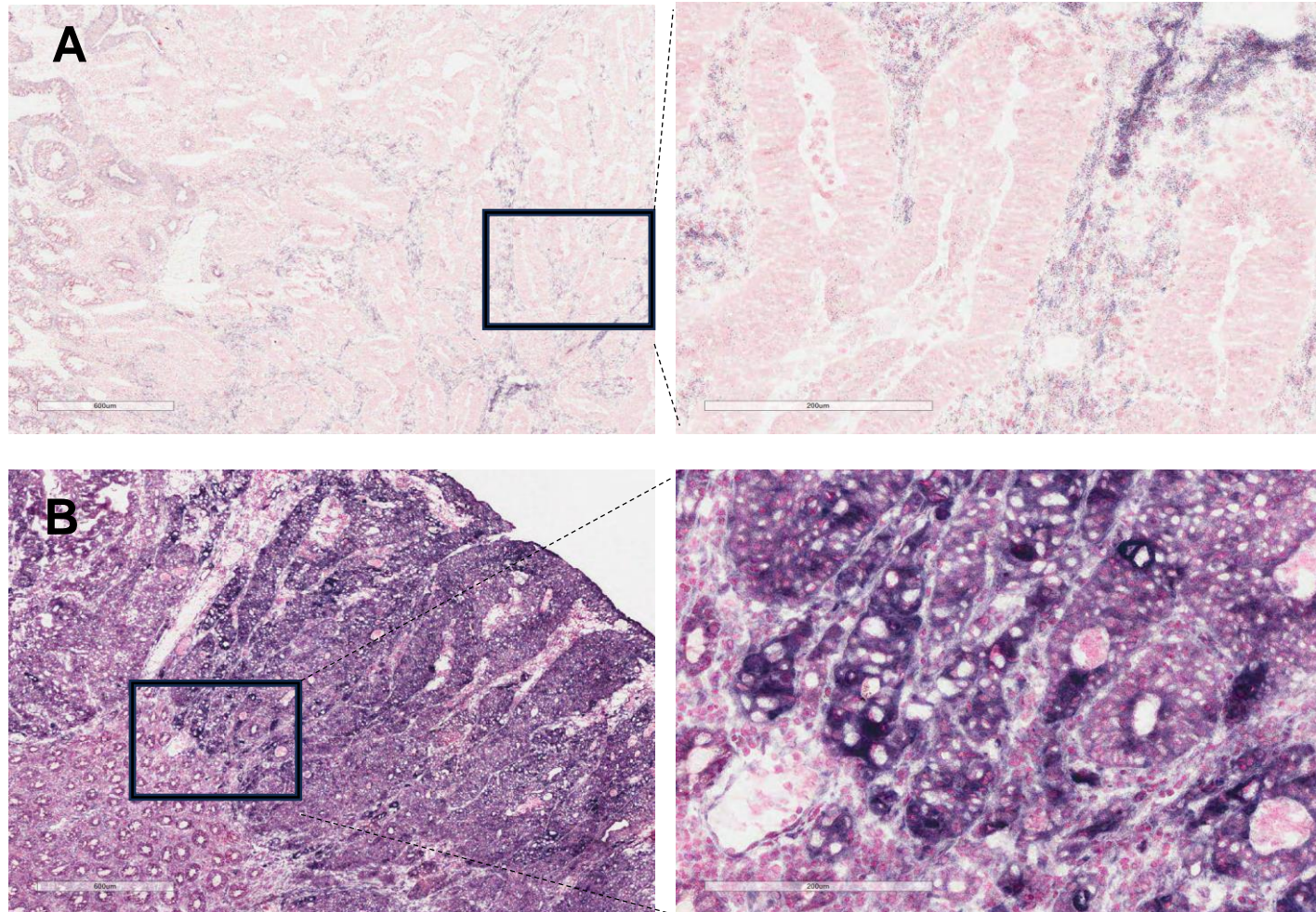


Fig. S3

NADH-TR staining

Primary colorectal cancer



Supplementary Fig. S3. Nicotinamide adenine dinucleotide dehydrogenase–tetrazolium reductase (NADH-TR) staining results in human colorectal cancer tissues. (A) The staining result of NADH-TR–low patient. (B) The staining result of LADH-TR–high patient.